

Microsurgical replantation of the amputated penis with concomitant arterialization of the dorsal vein in a 17-year-old patient

Janusz Darewicz, Lech Gałek, Barbara Darewicz, Tadeusz Werel, Krzysztof Rogowski

Department of Urology, Medical University, Białystok, Poland

key words: penis • traumatic amputation • replantation • deep dorsal vein arterialization

SUMMARY

Background: Among traumas of the external sex organs, amputation of the penis is one of the rarest. In most cases it is a result of self-mutilation and rarely of an accident.

Case report: A rare case of penis amputation in a 17-year-old boy is presented. The accident resulted from being hit with a toothed wheel of a chaff-cutter. The penis was replanted 14 hours after the accident. Considering the inability to reconstruct the arterial vessels, arterialization of the deep dorsal vein was performed. In the post-operative period, congestion of the penile veins with subsequent necrosis of the organ occurred.

Conclusions: We believe that ensuring sufficient efflux of venous blood is one of the factors most important for a successful outcome of microsurgical penis replantation.

BACKGROUND

Among the traumas of the external sex organs amputation of the penis is one of the rarest. In most cases it is a result of self-mutilation and rarely of an accident [1]. In this report, we present the case of a 17-year-old boy with a severed penis, the second of its kind described by us in the literature. However, it is the first one in which conditions for local efflux of arterial blood in the organ were created through arterialization of the dorsal vein of the penis [2].

CASE REPORT

A 17-year-old boy, M. J., was admitted to the Department of Urology, Medical University, Białystok, Poland, on 9.04.1998 because of severed penis. The accident occurred while working on a farm. His penis was severed right through his clothes by a toothed wheel of a chaff-cutter. The physician from the Emergency Squad placed the severed organ in saline

solution and ice, tightly bandaged the perineum and transported the patient to the Department of Surgery at the Regional Hospital in Ostrzeszów. Because of bad weather conditions, the patient had to wait 12 hours before being transferred to the Dept. Of Urology at the Medical University of Białystok.

On examination, a jagged wound of the perineum and crushed tissue of the remnant penis stump were noted (Figure 1). The amputated penis had been placed in a bag with saline and covered with ice.

Under general anesthesia, the wound and the penis stump were cleaned and the vessels of the amputated penis were perfused with heparin solution. Then suprapubic urine diversion was performed and the urethra was anastomosed with Vicryl 4-0 single stitches on an U-shaped polyethylene drain. Tunica albuginea of the penis was anastomosed with continuous Vicryl 4-0 suture. Considering the character of the wound and tissue damage, only the dorsal superficial vein and the deep dorsal vein of the penis were identified among the vessel elements. The dorsal artery was not found. Using an operating microscope (Opton, Germany) the anastomosed superficial vein was sutured with single stitches using

Author's address: Prof. Janusz Darewicz MD, PhD, Department of Urology, Medical University, ul. M. Skłodowskiej-Curie 24a, 15-276 Białystok, Poland, email: urolamb@cksr.ac.bialystok.pl

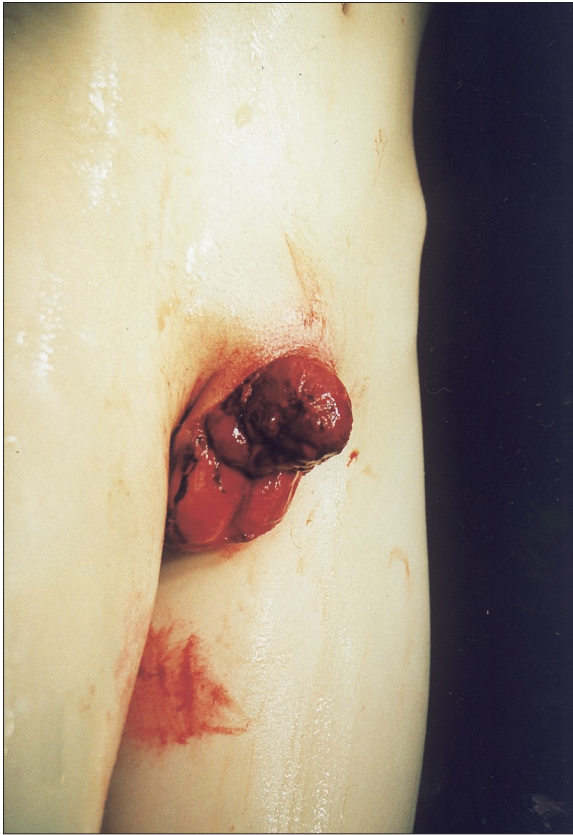

Figure 1. The jagged wound of the perineum with the penis stump covered with blood clots.

Prolene 8–0. A 2 cm loss of the deep dorsal vein made it impossible to anastomose it end to end. In order to create continuity of the vessel, a Y-shaped section of vein was taken from the patient's foot. Its lateral branch was anastomosed end to end with preprepared and relocated to the subcutaneous canal of inferior epigastric artery using Prolene 10–0 single stitches.

The temperature of the penis was normal immediately after the operation (Figure 2). In the post-operative period, broad-spectrum antibiotic and anticoagulants were introduced (Fraxiparine, Aspirin). In the first few days after the surgery, congestion of the penis veins with cyanosis of the tissue was observed. After 2 weeks, aseptic necrosis of the organ developed necessitating its subsequent amputation. The wound healed through granulation of the tissue and the suprapubic drainage tube was removed. Three months after the surgery, the patient was transferred to the Clinic of Plastic Surgery for reconstruction of the penis.

DISCUSSION

Considering the rarity of amputation of the penis, such cases are reported in the literature as descrip-

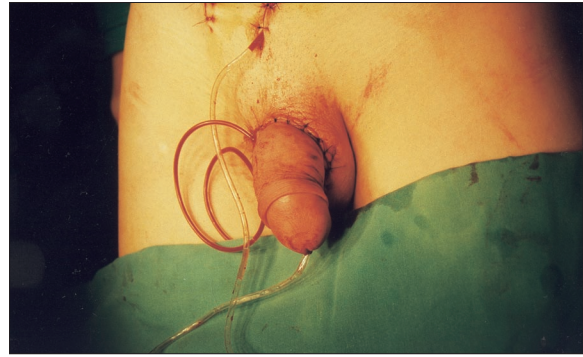


Figure 2. After the replantation.

tions of accidents [3]. Successful resuturing of the organ can be generally divided into 2 methods: the macroscopic replantation or reimplantation with microsurgical anastomosis of the arteries and nerves [4]. Anatomical structure and blood vessel properties of the penis make successful replantation by the macroscopic method possible [5]. The prerequisites for a positive outcome include restoring normal blood flow and the time elapsed from the accident to surgery. In the described cases, successful outcome of the surgery is better attained up to 6 hours after the accident [6].

Microsurgical replantation of the penis is at present the method of choice in cases of complete amputation of the organ [3,7,8]. Creating continuity of the main vessels, restoration of physiological conditions of microcirculation, insures an equally good cosmetic effect as well as normal erectile function while preserving perception within the glands [9]. Anastomosing of the nerves is equally required in these cases [4].

The penile tissues possess good ischemic tolerance which is additionally increased through hypothermia making successful replantation possible even 16 hours after the accident [10]. That is also why, in spite of the 12 hours delay and taking into account the patient's young age and the correct procedures carried out by the Emergency Rescue Squad physician, we decided to try to reconstruct the organ in this case. The long period of time which had elapsed from the accident, the state of the injury and the inability to reconstruct the arterial vessels were all factors for an adverse prognosis. That is also why in order to ensure proper blood supply to the sutured organ we performed arterialization of the deep dorsal vein of the penis. The reason we performed that was the lack of the main vessels (about 2 cm). Additionally, this type of procedure is used with good results in the treatment of vasculo-

genic impotence [11]. Unfortunately, it may have caused difficulty in the venous outflow in this case, firstly because of high pressure in the venous system and secondly due to damage of other veins draining blood from the penis.

In the post-operative period, congestion of the veins with subsequent necrosis of the sutured penis occurred. We believe that the main reason for failure was the microembolisms in the arterial and venous capillary system resulting in insufficient venous drainage [12].

CONCLUSIONS

In conclusion, we believe that the primary conditions for a successful outcome are the time factor from the moment of accident to surgery, as well as creating conditions for sufficient efflux of venous blood.

REFERENCES:

1. Becker M, Höfner K, Lassner F et al: Replantation of the complete external genitals. *Plast Reconstr Surg*, 1997; 99: 1165-1168
2. Matloub HS, Yousif NJ, Sanger JR: Temporary ectopic implantation of an amputated penis. *Plast Reconstr Surg*, 1994; 93: 408-412
3. Fan J, Eriksson M, Rosenlund AF, Nordström RE: An unusually avulsed penis successfully replanted by using microsurgical technique. *Plast Reconstr Surg*, 1996; 98: 571-573
4. Lowe MA, Chapman W, Berger RE: Repair of a traumatically amputated penis with return of erectile function. *J Urol*, 1991; 145: 1267-1270
5. Jordan GH, Gilbert DA: Management of amputation injuries of the male genitalia. *Urol Clin North Am*, 1989; 16: 359-367
6. Bux R, Carroll P, Berger M, Yarbrough W: Primary penile reanastomosis. *Urology*, 1978; 11: 500-503
7. Darewicz J, Galek L, Malczyk E et al: Microsurgical replantation of the amputated penis and scrotum in a 29-year-old man. *Urol Int*, 1996; 57: 197-198
8. Sanger JR, Matloub HS, Yousif N J, Begun FP: Penile replantation after self-inflicted amputation. *Ann Plast Surg*, 1992; 29: 579-584
9. Jimenez-Cruz JF, Garcia-Reboll L, Alonso M et al: Microsurgical penis replantation after self-mutilation. *Eur Urol*, 1995; 27: 246-248
10. Wei FC, McKee NH, Huerta FJ, Robinette MA: Microsurgical replantation of a completely amputated penis. *Ann Plast Surg*, 1983; 10: 317-321
11. Virag R, Saltiel H, Floresco J et al: Surgical treatment of vascular impotence by arterialization of the dorsal vein of the penis. Experience of 292 cases. *Chirurgie*, 1988; 114: 703-714
12. Ishida O, Ikuta Y, Shirane T, Nakahara M: Penile replantation after self-inflicted complete amputation: case report. *J Reconstr Microsurg*, 1996; 12: 23-26