



Case Report

SUCCESSFUL MICRONEUROVASCULAR PENILE REPLANTATION USING LOUPE MAGNIFICATION FOLLOWING SELF AMPUTATION IN A YOUNG PATIENT

Tanveer Ahmed¹, Zakir Hossain², Lutfar Kader Lenin³

Abstract

Amputation of the penis is a rare condition reported from various parts of the world. They reported as isolated cases or small series of patients in scientific research. The common etiology is self amputation by sharp weapon or an avulsion or crush injury in an industrial accident or following violence. Complete reconstruction of anatomical structures should be done in one stage which provides the best chance for full rehabilitation of the patient. We report here a single case of sub-total amputation of the penis at its proximal third in a schizophrenic patient. The penis was successfully replanted using a microsurgical technique. After surgery, near-normal appearance and function including a good urine flow and absence of urethral stricture, capabilities of erection and near normal sensitivity were observed.

Keywords: *Penile replantation, penile amputation, microsurgery*

Introduction

Traumatic penile amputation is a rare condition requiring urgent surgical attention with almost immediate surgical intervention¹. About 87% of the patients reported had psychiatric problems. Although seen in both paediatric and adult populations, the majority are seen in the latter age group. Self-amputation of external genitalia is also known as Klingsor syndrome. A few patients had poor gender identity feeling themselves inadequate as males. Some cases arise from felonious assault by jealous homosexual lovers. These injuries are usually occurring with the organ flaccid and most are self-

inflicted by mentally unstable patients^{2,3}. In 1970 in Thailand, an epidemic was seen, of penile amputation as punishment for philandering by humiliated wives⁴. Micro-neuro-vascular penile replantation offers the best prospect for restoration of micturition function, return of sensations and erectile functions. These cases highlights the management of such a patient not only in the operative room but also in the emergency resuscitation room^{4,5}.

Currently replantation involves meticulous microsurgery to reduce the possibility of skin, urethra and graft loss but these complications may still occur. Microsurgical replantation means the repair of vessels and nerves. Non-microsurgical techniques also have good post-operative outcomes but not much as microsurgical repair. This report describes a case of microsurgical replantation of traumatic self-amputation of penis in an 18 year old boy using 2.5× loupe magnifications to restore a functional, fully erectile penis with minimum tissue loss^{6,7}.

1. Resident Plastic Surgeon, Dhaka Medical College Hospital
2. Associate Professor of Plastic Surgery, Sir Salimullah Medical College and Mitford Hospital
3. Assistant Professor of Plastic Surgery, Dhaka Medical College and Hospital

Corresponding author: Dr. Tanveer Ahmed, FCPS (Plastic Surgery). Resident Plastic Surgeon, Department of Plastic Surgery, Dhaka Medical College Hospital, Bangladesh. E-mail: tahimon@gmail.com.

Received: 12 September 2013 **Accepted:** 05 December 2013

Case Report

We report the case of an 18 year old boy with schizophrenia who presented in emergency and casualty department with the history of cutting his penis with a sharp shaving blade 3.5 cm distal from the root. Immediately after the self mutilation the amputated penis was fallen into the floor and mixed with dusts. His father collected the amputated part and cleaned with tap water (which should not be done) and put inside a polyethylene bag. The patient presented at our hospital eight hours later. Bleeding from the proximal penile stump was stopped by a pressure bandage in a district hospital. The patient was prepared for emergency general anesthesia. The patient was given anti tetanus prophylaxis by means of 1500 units of anti-tetanus serum and 2 ml of tetanus toxoid just after initial evaluation. Intravenous administration of 1 gm ceftriaxone along with 500 mg metronidazole was given. Three units of fresh whole human blood were arranged. As the patient had lost blood before coming to our hospital, we transfused two units in the emergency room. We found a clear cut injury through all penile structures without major lacerations at approximately 3.5 cm from the root of the penis.

Gross cleaning of the wound and the penile amputated part was carefully cleaned with cold sterile normal

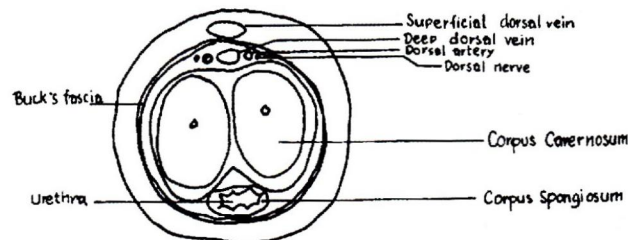


Fig.-1: Diagrammatic picture showing the cross-section of the penis

saline followed by meticulous debridement using loupe magnification. The following steps were followed in sequence:

- a) Bleeding from the proximal stump was controlled by application of vascular clamps. After identification of all main vessels, the distal and proximal ends of both dorsal arteries were clipped with vascular clamps and both ends of the urethra together with the corpus spongiosum were mobilized.;
- b) Under loupe magnification, the ends of the dorsal arteries and a dorsal vein, and nerve were identified;
- c) The amputated part was then put on a 16F silicone Foley catheter, which was passed into the patient's bladder to stabilize both ends before anastomosis. The urethral ends were spatulated. To achieve a stable basis, the tunica albuginea of both corpora cavernosa and the septum were attached by suture using 5-0 polyglycolic acid (vicryl) suture. The urethral mucosa of both ends approximated by interrupted 6-0 chromic catgut and the adventitia and corpus spongiosum by 5-0 vicryl suture (**Figure 2**);
- d) The deep corporeal arteries were identified but failed to anastomose. After irrigation with heparinized saline, only one deep dorsal artery was anastomosed with 8-0 prolene sutures. Next the deep dorsal vein and the two nerves were anastomosed using 8-0 prolene.
- e) Buck's fascia was closed with 5-0 vicryl and then the superficial vein was anastomosed with 8-0 prolene.
- f) Finally, the skin was closed with 5-0 prolene. Glans was fixed with the catheter by 4-0 silk.

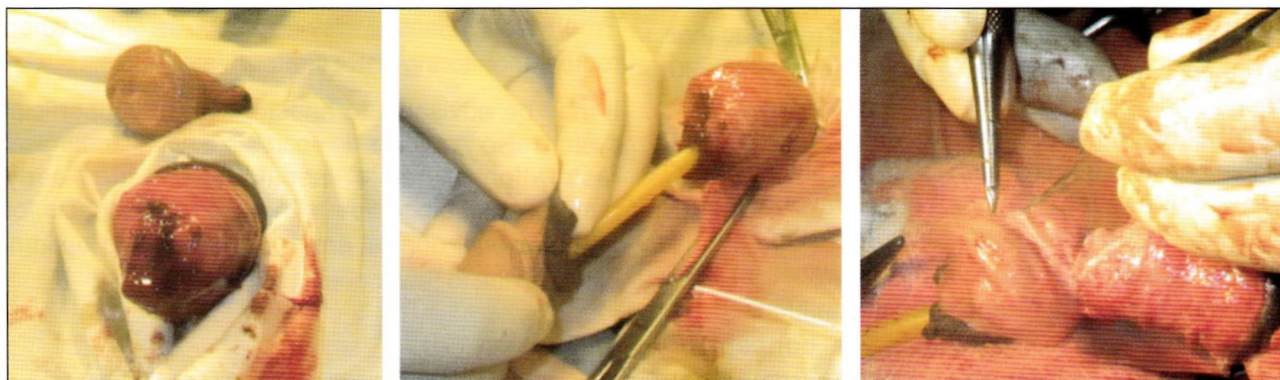


Fig.-2: (Left to right) Showing the amputated parts of the penis. Foley catheter was put in the distal amputated segment and passes to urinary bladder. Microvascular repair is going on.

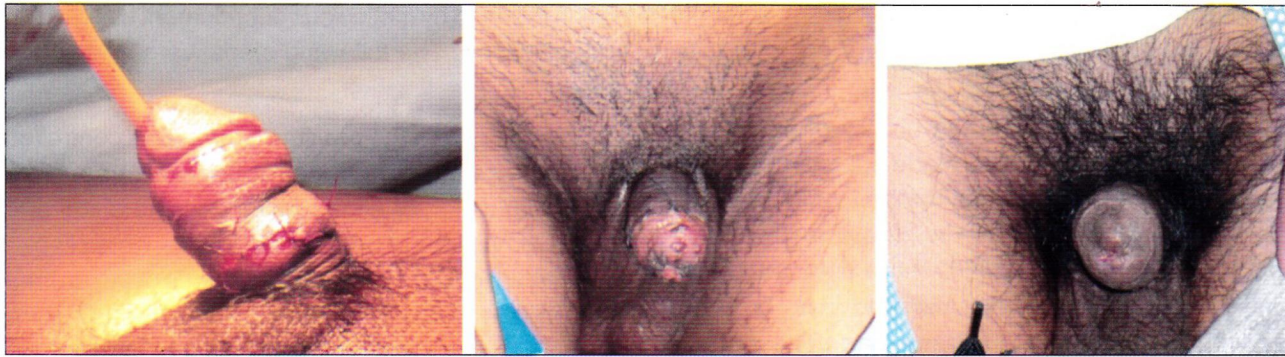

Fig.-3: (Left to right) Showing the penis just after replantation and skin closure, presence of good circulation is seen. In the middle, on 4th post-operative week after catheter removal. Final follow up on 6th post-operative week.

Then a gentle pressure dressing was applied around the penile shaft and the penis was fixed in an upright fashion. Transurethral catheter was kept for 21 days. Patient was transferred in to the post-operative ward keeping him warm, well hydrated and pain free. Besides the normal post-operative medication and care sedative was prescribed. Tab. Largactil (chlorpromazine hydrochloride) was given three times a day to make him sedated. On the fifth postoperative day, patient was taken to change the dressing in sterile precautions. After the first ten post-operative days the patient developed partial necrosis of the tip of the glans that had to be resected. More than 70% of the glans remained intact. The catheter was removed after four weeks. Retrograde urethrography was performed following catheter removal after six weeks and no leak was identified. Postoperative psychiatric consultation was advised.

Discussion

The first documented case of macroscopic penile replantation was reported in 1929 by Ehrlich. Cohen *et al.* reported the first microvascular replantation of penis in 1977². A review of the literature revealed that 80 cases underwent penile replantation, of which 30 cases underwent microsurgical replantation since 1970. These 30 cases have been reported to be of higher quality in terms of both functional and aesthetic result^{2,8}. Many factors contribute to favorable final outcomes⁹. Analysis of the cases revealed that the cleanly incised injury with a short duration of cold ischemia was an important factor that influenced the outcome. Another factor was the concept of microsurgical replantation. The macrosurgical replantation of the penis depends on corporal sinusoidal blood flow with the distal amputated part

as a composite graft leading to high complication rates of skin necrosis, fistula formation, loss of sensations and erectile dysfunction. In contrast, the microsurgical approximation of the penile shaft structures provides early restoration of blood flow with the best prospects for survival, normal erectile function and optimal benefits with fewer complications^{2,4}. Another critical factor for the success of replantation was the adequacy of venous outflow and the sequence of microsurgical anastomosis. Due to the dual vascular drainage in the penis, the superficial and deep dorsal veins, tributaries of saphenous and santorini plexus respectively, were both anastomozed for good venous return. The return of penile sensations over the glans was as expected in the yearly follow-up of the cases⁷. In our opinion, another important factor was the critical postoperative monitoring of the replantation. Timely intervention was done in the form of release incisions to relieve edema and maintain vascularity of the penis. The initial raw areas may appear as disfiguring but the final result was satisfactory, with near uniform girth of the penile shaft. We suggest similar measures to protect the anastomosis and prevent failure. Prophylactic release incisions can be an option when regular monitoring is not contemplated^{9,10}.

It may be advisable to anastomoz the superficial system also to avoid skin necrosis. The microsurgical restoration of penile vascularity provides early restoration of blood flow with the best prospects for graft survival, normal erectile function and optimal benefits due to fewer complications^{11,12}.

Conclusion

The ultimate goal of penile replantation is to restore a functional and aesthetic penis. Expedient penile reconstruction is essential and delay is associated

with complications. Microvascular techniques should be used in penile amputation at any level. The replanted penis receives blood supply from deep dorsal vessels in the early stage and could survive independent from these vessels after the continuity of the sinusoid was established weeks after surgery. For penile amputation, microvascular replantation is the treatment of choice. Microsurgical anastomoses of the vessels and nerves provide preservation of sensation, physiologic micturition, and normal erectile function.

Acknowledgements: Dr. Salma Sultana, for her support to use the casualty operating theatre and Dr. Liman Kumar Dhar for following the patient.

Source of Support: Nil

Conflict of Interest: None

References

1. Yeniyol CO, Yener H, Keçeci Y, Ayder AR. Microvascular replantation of a self amputated penis. *Int Urol Nephrol*. 2002;33:117-9.
2. Babaei AR, Safarinejad RM. Penile replantation-Science or myth? A systematic review. *J Urol*. 2007;4:62-5.
3. Fuller A, Bolt J, Carney B. Successful microsurgical penile replantation after a workplace injury. *Urol Int*. 2007;78:10-2.
4. Bhangananda K, Chaiyavātana T, Pongnumkul C. Surgical management of an epidemic of penile amputations in Siam. *Am J Surg*. 1983;146:376-82.
5. Kochakarn W, Muangman V, Krauwit A. Traumatic penile amputation: Results with primary reattachment. *J Urol*. 1997;157:857.
6. Aydin A, Aslan A, Tuncer S. Penile amputation due to circumcision and replantation. *Plast Reconstr Surg*. 2002;110:707-8.
7. Jordan GH, Gilbert DA. Management of amputation injuries of the male external genitalia. *Urol Clin North Am*. 1989;16:359-67.
8. Volker BG, Maier S. Successful penile replantation following auto amputation twice. *Int J Impot Res*. 2002;14:197-8.
9. Kochakarn W. Traumatic amputation of penis. *Braz J Urol*. 2000;26:385-9.
10. Schweitzer I. Genital self amputation and the klingsor syndrome. *Aust Nz J Psychiatry*. 1990;24:566-9.
11. Cohen BE, May JW, Dalsy JS, Young HH. Successful clinical replantation of an acute amputated penis by microvascular repair. *Plast Reconstr Surg*. 1997;59:276-80.
12. Darewicz B, Galek L, Darewicz, Malezyk E. Successful microsurgical replantation of an amputated penis. *Int Urol Nephrol*. 2001;33:385-6.