

J. Darewicz  
L. Gątek  
E. Malczyk  
B. Darewicz  
K. Rogowski  
J. Kudelski

Department of Urology,  
Medical School Białystok, Poland

## Microsurgical Replantation of the Amputated Penis and Scrotum in a 29-Year-Old Man

.....  
**Key Words**

Replantation  
Automutilation  
Genital organs

.....  
**Abstract**

A 29-year-old mentally ill farmer underwent microsurgery for the resuturing of the penis and testicles which he himself had chopped off with an ax. Microsurgery of the urethra, corpora cavernosa, arteries and veins was begun 10 h after the trauma. The veins, arteries and testicles were anastomosed and covered with a free flap of the scrotum skin. Three weeks after surgery, the anastomosed tested showed good healing. However, in 65% of the penis, necrosis had occurred.  
.....

**Introduction**

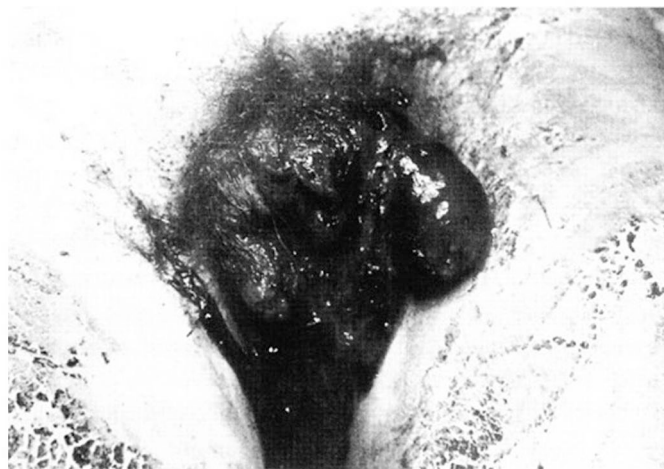Among the traumas of the genitourinary tract, severance of the penis and scrotum is very rarely observed [1]. Automutilation is usually associated with mental illness [2]. In 1 reported case, the loss of the penis and testicles was the consequence of a street fight [3]. To our knowledge, there are only 3 such cases described in the literature.

**Case Report**

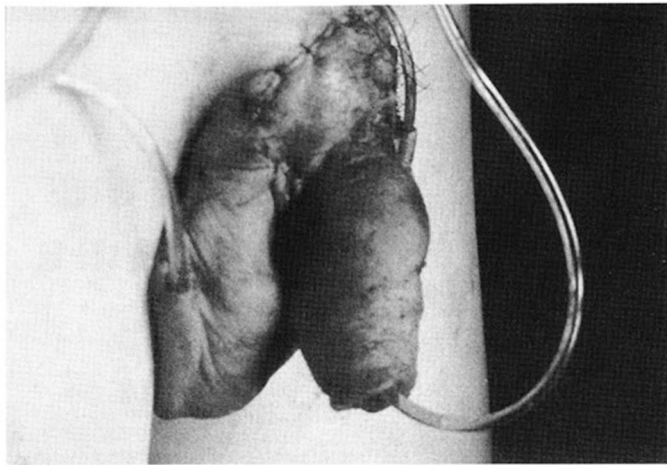
A 29-year-old farmer with a history of mental illness was admitted to the Department of Urology, Medical School Białystok, Poland, on December 30, 1994, for autoamputation of the penis and scrotum. He had used a block of wood and an ax in his backyard to accomplish this at 1 a.m. After remaining in the yard for a few hours (temperature 4°C), he returned to the house and lost consciousness from loss of blood. The emergency squad was called. The genitalia were placed in a container of saline and ice and transported along with the patient to our Clinic. The patient refused to divulge the reason for the automutilation.

He informed us that he had been hospitalized twice in a psychiatric hospital for depression. At physical examination, total amputation of the penis, both testicles and all the skin from the scrotum was noted. The wound was covered with blood clots (fig. 1). The genitalia were perfused and placed in Collins' solution at a temperature of 4°C. Under general anesthesia the wound was cleaned, and a median lower incision was made to open the urinary bladder. A U-shaped

polyethylene drain was inserted. One of its endings was brought out through the urethra stump. The amputated penis was then anastomosed in a first step with a semicircular suture of the urethra and next with a continuous suture of the corpora cavernosa. The ending of the U drain protruded through the external opening of the urethra. Under the operating microscope (Opton, Germany) the deep dorsal veins and dorsal arteries of the penis were anastomosed end to end, using Prolene 8-0 sutures. The dorsal veins were anastomosed in the same way. After identifying the arteries and veins, the spermatic



**Fig. 1.** The wound covered with blood clots.



**Fig. 2.** After the replantation.

duct, left testicular artery and vein were anastomosed. The suturing of the deferential artery with Prolene 10-0 was performed because the vessels were severed just short of the testicle on the right side. The testes were covered with a skin flap from the scrotum (fig. 2). The temperature of the penis was normal at the end of the operation. While taking a specimen for histopathological examination of the testes, a good blood outflow was observed. After surgery, broad-spectrum antibiotics and anticoagulants were given for 14 days. Two weeks after the operation, necrosis of the penis and the skin of the scrotum occurred. The testes were covered with granulated tissue. Three months later, the patient was transferred to the Clinic of Plastic Surgery for reconstructive surgery of part of the penis.

## Discussion

The success of replantation depends on a number of factors, the most important of which are cooling the severed organ and precise microsurgical replantation. The ischemic time for the penis tissue using refrigeration is still undefined. Successful replantation after a 5-hour period of ischemia [4] and also after 14 [3] and 16 h [2] have been described. In 1974, Hayhurst et al. [as quoted in 2] demonstrated that hypothermia may prolong the ischemic time and survival of the replantation tissue even as long as 24 h. The penis tissue has good ischemic tolerance and replantation should be performed especially when refrigeration is applied. The ischemic time for the testes is about 2 h. Four hours of ischemic time cause some disturbances, but 6-hour ischemia results in permanent loss of spermatogenesis [5]. Endocrine function has been observed even after 16 h of ischemia [2]. During microsurgical replantation of the penis, special attention should be paid to anastomosing the two dorsal arter-

ies and both superficial and deep veins. This is important for the prevention of sexual impotence. Reconstruction of the nerve continuity would prevent disorders of perception. During reimplantation of the testes, it is important to remember that the testicular arteries are the terminal-vessels and that ligation of their branches may have a serious influence on healing and regaining their function [5]. Precise anastomosis of the urethra plays an important role during reimplantation of the penis because of the blood flow through the spongy body. Incorrect anastomosis results in delayed healing of the urethra and may lead to the development of a urinary fistula.

Anticoagulant administration is a controversial issue. After their administration, some authors have observed necrosis of the testes and penis [6]. Others who had not used heparin did not observe necrosis even after several hours of ischemia [2].

In the present case despite hypothermia, precise microsurgical anastomosis of the vessels and anticoagulation two thirds of the penis became necrotic. We assume that an important role was played by another factor, perhaps by microemboli of red blood cells. Blood flow was restored 10 h after amputation.

In conclusion, it should also be stressed that the psychological state at the time of the autoamputation and the postoperative period is a major factor in the healing process.

## References

- 1 Henriksson TG, Hahn B, Hakelius L, Lantto S, Norlen BJ: Microsurgical replantation of an amputated penis. *Scand J Urol Nephrol* 1980; 14:111-114.
- 2 Wei FC, McKee NH, Huerta FJ, Robinette MA: Microsurgical replantation of a completely amputated penis. *Ann Plast Surg* 1983;10: 317-321.
- 3 Szasz G, McLoughlin MG, Warren RJ: Return of sexual functioning following penile replant surgery. *Arch Sex Behav* 1990;19:343-348.
- 4 Tamai S, Nakamura Y, Motomiya Y: Microsurgical replantation of a completely amputated penis and scrotum. *Plast Reconstr Surg* 1983;60:287-291.
- 5 Xu Y, Wu P, Chai P, Chen Z: Replantation of the testis: Report of a case. *J Urol* 1988;139: 596-598.
- 6 Abbou CC, Servant M, Bonnet F, Chopin D, Alasseur F, Grellet M, Auvert J: Réimplantation du pénis et des deux testicules après auto-émasculature complète. *Chirurgie* 1979;105: 354-357.